

“Açık ve Laparoskopik Cerrahide Fiksasyonsuz Onarım”

Koray TOPGÜL

Ondokuz Mayıs ÜTF Genel Cerrahi AD/ Samsun



Laparoskopik Kasık Fıtığı Onarımı

- Daha az postoperatif ağrı
 - Hızlı iyileşme
- Eerken normal aktiviteye dönüş

Barkun JS et al; Surgery 1995

Tanphiphat C et al; Surg Endosc 1998

- Tekrarlama (nüks)

- Ağrı

- Enfeksiyon

- Damar yaralanması

- Testiküler atrofi

- İş-güç kaybı

Tekrarlama -----küçük yama

yetersiz tespitleme

yamanın migrasyonu

atlanmış fitik

deneyimsizlik

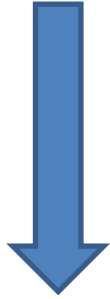
Ağrı ----- zimba ile sinir sıkışması

zimba nedeniyle pubalji

yamanın sinirler üzerine lokal etkisi

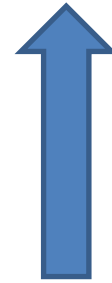
Fıtık Cerrahisi

Tekrarlama



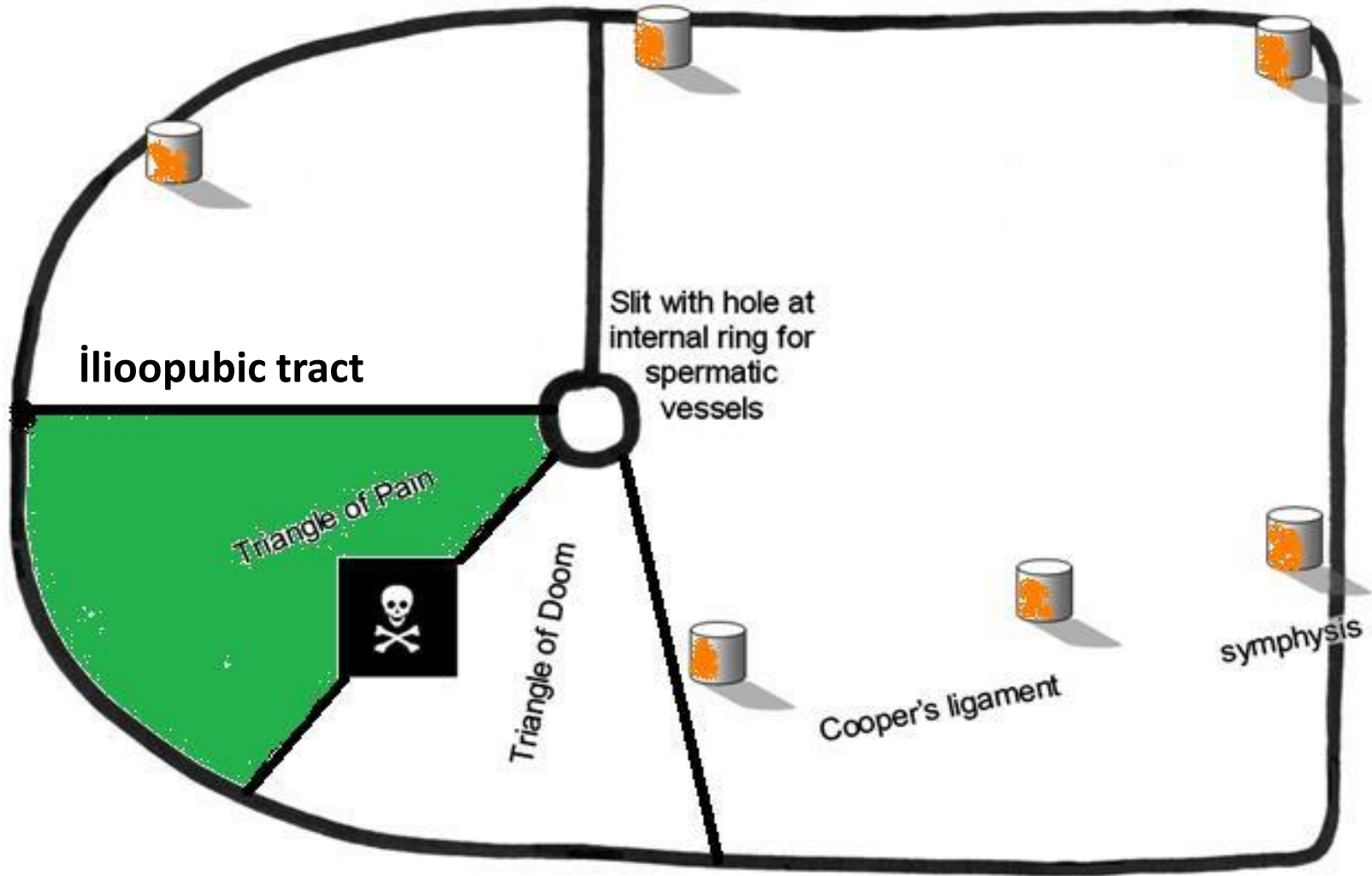
OUT

Ađrı



IN

İçerden Sol Kasık



B. Novik et al. Fibrin glue for securing the mesh in laparoscopic totally extraperitoneal inguinal hernia repair. Surg Endosc (2006)

Komplikasyonlardan nasıl
kaçınabiliriz?

(Ađrı ve tekrarlama riskini artırmadan!)

- **Zimba kullanmalıyız**, ancak az sayıda ve büyük bir dikkatle.
- **Tespitlemeye gerek yoktur**, uygun boyutta yamayı iyi bir teknikle kullanıyorsanız.
- **Fibrin yapıştırıcı**, tekrarlama riskini artırmadan ağrı insidansını azaltan bir yöntem olarak uygundur

*«Tespitleme yapalım mı
yapmayalım mı?»»*

Daha önceki yayınlar

Tekrarlamadan kaçınmak için yama tespitlenmelidir

Daens GT et al. Br J Surg; 1995

Felix E et al. Surg Endosc; 1998

Lowham AS et al. Ann Surg; 1997

Ancak zımba kullanımı sinir hasarına ve kronik ağrıya
neden olabilir

Andrew DR et al. Et al. Br J Surg; 1994

Chevallier JM. Ann Chir; 1996

Stark et al. Surg Endosc; 1999

Laparoscopic inguinal hernia repair without mesh fixation, early results of a large randomised clinical trial

Craig Taylor · Laurent Layani · Victor Liew · Michael Ghusn ·
Nic Crampton · Stephen White

Table 3 Incidence of new and persistent groin pain

	Fixation	No fixation	<i>p</i> value
Any new pain	38%	23%	0.0003
Pain score ≥ 2	22%	15%	0.049
≥ 3	16%	8%	0.009
≥ 4	2%	Nil	0.06

Conclusion

Mesh fixation appears to be unnecessary in TEP repair of small hernial defects. It is associated with higher operative costs and an increased likelihood of developing chronic groin pain. The omission of mesh fixation did not increase the risk of early hernia recurrence.

***500 fıtık, 2004-2006, prospektif çok merkezli çift kör randomize , TEP, 6-13 ay takip**

***Tespitleme grubunda bir tekrarlama (%0.2)**

***Tespitleme yapılmayan grupta hasta başına maliyette azalma 375 AUD**

Total Extraperitoneal Laparoscopic Inguinal Hernia Repair Without Mesh Fixation

Prospective Study With 1-Year Follow-up Results

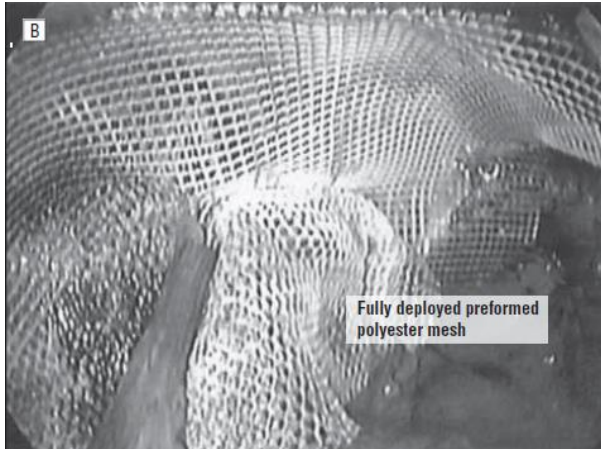
Evangelos Messaris, MD, PhD; Guy Nicastrri, MD; Stanley J. Dudrick, MD

ARCH SURG/VOL 145 (NO. 4), APR 2010

*311 fıtık

*%96 'sı bir yıl takip edilmiş

*polyester ve slit yama



Tekrarlama yok

%6.1 seroma

Kronik ağrı yok

350-450 USD karlı

**Deneyimli cerrahla için
laparoskopik onarımda
tespitlemeye gerek yoktur!**

Randomized Prospective Study of Totally Extraperitoneal Inguinal Hernia Repair: Fixation Versus No Fixation of Mesh

Cody A. Koch, Susan M. Greenlee, RN, Dirk R. Larson, MS,
Jeffrey R. Harrington, MA, David R. Farley, MD

JSLs (2006)10:457-460

2002-2004, prospective randomized, two groups-- with or without tacking

Postoperative pain levels were lower in patients who did not receive mesh fixation ; however, the difference was not significant

No recurrence and no nerve injury

Conclusion: They recommended tackless endoscopic TEP inguinal hernia repair in selected patients.

Randomized Clinical Trial of Fixation vs Nonfixation of Mesh in Total Extraperitoneal Inguinal Hernioplasty

Alfredo Moreno-Egea, MD; José Antonio Torralba Martínez, MD;
 Germán Morales Cuenca, MD; José Luis Aguayo Albasini, MD

ARCH SURG/VOL 139, DEC 2004

COMMENT

efficient, as with anterior hernioplasties. Along this line, our study shows that hospital cost can be reduced by eliminating the routine use of mesh fixation. A suture gun in our center costs around €400; thus if in 2003 we operated on 116 inguinal hernias via laparoscopy, the cost of this item amounts to €46600. By selecting patients in whom to fix the mesh, together with large-sized direct and bilateral cases (200 cases in 2003), we could create a considerable saving (€38400/y). These data may be of great interest for departments planning to set up as clinical management units.

In conclusion, mesh fixation in the TEP technique offers no clinical advantages and increases the cost of the process. Our results recommend limiting the use of mesh fixation in the laparoscopic approach to cases of direct bilateral hernias.

Table 2. Morbidity of the 2 Groups of Patients Undergoing Surgery for Inguinal Hernia, According to Mesh Fixation*

Mesh Fixation	Total Extraperitoneal Laparoscopic Inguinal Hernioplasty		P Value
	No (n = 85)	Yes (n = 85)	
Anesthesia, general/spinal	57/28 (32.9)	72/13 (15.3)	.01
Operating time, min, mean ± SD			
Unilateral	39.1 ± 15.3	45.7 ± 17.9	.01
Bilateral	44.2 ± 22.6	50.5 ± 19.2	.05
Intraoperative morbidity	3 (3.5)	5 (5.9)	.36
Bleeding	0	3	
Wound infection	1	0	
Transitory neuralgia	2	2	
Postoperative morbidity	11 (12.9)	13 (15.3)	.32
Bleeding	10	11	
Wound infection	0	1	
Transitory neuralgia	1	1	
Hospital admission	3	8	
Ambulatory surgery	82 (96.4)	77 (90.6)	.31
Failures	2 (2.4)	4 (5.2)	
Pain, visual analog scale score, mean ± SD			
24 h	1.65 ± 1.3	1.78 ± 1.4	.26
1 mo	0.14 ± 1.7	0.16 ± 0.6	.46
No. of analgesics consumed, mean ± SD	4.73 ± 6.32	5.69 ± 7.69	.18
Time of analgesic consumption, d, mean ± SD	2.7 ± 5.48	3.03 ± 4.81	.34
Chronic pain	1 (1.2)	1 (1.2)	.75
Orchitis	0	0	
Recurrence	3 (2.7)	0	.11

*Values are expressed as number (percentage) of patients unless otherwise indicated.

Laparoscopic total extraperitoneal inguinal hernia repair with nonfixation of the mesh for 1,692 hernias

Pankaj Garg · Mahesh Rajagopal · Vino Varghese · Mohamed Ismail

Surg Endosc (2009) 23:1241–1245

	Mesh fixed (61 hernias/33 patients), <i>n</i> (%)	Mesh not fixed (1,692 hernias/896 patients), <i>n</i> (%)	<i>p</i> -Value
Operating time (min)	32.1 ± 8.5	30.2 ± 6.0	0.22, NS (<i>t</i> -test)
Conversion to open procedure	1 (3.03)	0	NS
<u>Seroma formation</u>	<u>6/61 (9.8)</u>	<u>28/1652 (1.7)</u>	0.0008 (Fisher's exact test)
<u>Urinary retention</u>	<u>9 (27.3)</u>	<u>41 (4.6)</u>	<0.0001 (Fisher's exact test)
Hospital stay (days)	1.35 ± 0.49	1.06 ± 0.25	<0.0001 (<i>t</i> -test)
Return to normal activities (days)	9.88 ± 3.3	7.59 ± 1.3	<0.0001 (<i>t</i> -test)
<u>Pain at 1 month</u>	<u>8 (24.2)</u>	<u>30 (3.3)</u>	<0.0001 (Fisher's exact test)
Recurrence	0	2 (0.2)	NS

difficult dissection or large defects. This could have led to a bias. However the prime purpose of the study was to show that TEP repair without mesh fixation is safe and associated with low recurrence rates. The technical points that must be given special care are adequate dissection, proper size of the mesh used, and accurate placement of the mesh in the preperitoneal space.

From the findings of this study, we can conclude with reasonable confidence that TEP inguinal hernia repair performed without mesh fixation is safe and feasible with minimal recurrence rates.

Fibrin Yapıştırıcı?

(1) Biyolojik

fibrin glue
Autologous Platelet-Rich Fibrin Sealant

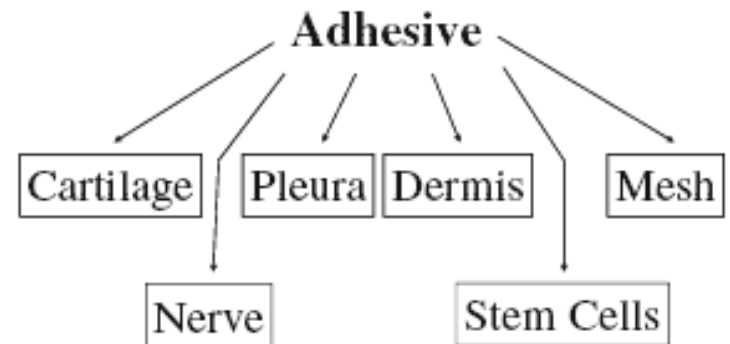
(2) Sentetik

cyanoacrylate glue

Fibrin Yapıştırıcı

Fibrinojen & Trombin

- Hemostas-z
- Sealants
- Adeziv



Byrne DJ, et al; Br J Surg, 1991

Spotnitz WD, et al; Transfusion therapy: clinical principles and practice, 2004

Spotnitz WD, World J Surg, 2010

Fixation materials in laparoscopic onarımda tespitleme materyalleri ---which one?

- EMS– Protack– EndoAnchor– Tisseel (FS)

in Tisseel group

- Less pain
- More rapid return to work
- Less seroma/hematoma
- No increase in recurrence

Olmi S, Surgery, 2007

Novik B, Surg Endosc , 2006

Use of Fibrin Sealant for Prosthetic Mesh Fixation in Laparoscopic Extraperitoneal Inguinal Hernia Repair

ANNALS OF SURGERY
Vol. 233, No. 1, 18-25 2001

Namir Katkhouda, MD, FACS,* Eli Mavor, MD,* Melanie H. Friedlander, MD,* Rodney J. Mason, MD, PhD,* Milton Kiyabu, MD,‡ Steven W. Grant, MD,* Kranti Achanta, MD,* Erlinda L. Kirkman, DVM,† Krishna Narayanan, MD,* and Rahila Essani, MD*

- **Graft motion---- FS=S>NF**
- **Tensile Strength---- FS=S>NF**
- **Histologic findings---FS >S= NF**
 - **1ml FS \$100**
 - **Hernia stapler \$170**

Less chronic pain following mesh fixation using a fibrin sealant in TEP inguinal hernia repair

Hernia (2006) 10: 272–277

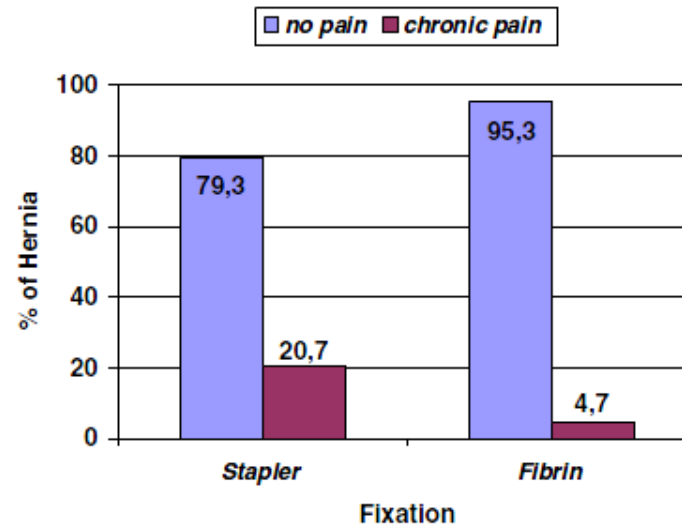


Fig. 2 Chronic inguinal pain: stapler versus fibrin sealant ($P=0.002$)*, *Fisher exact test

Schug-Pass C et al, Langenbecks Arch Surg;2010

Ceccarelli G, et al, Surg Endosc; 2008

Lovisetto F et al, Annals of Surgery; 2007

Olmi S et al, Surg Endosc; 2006

Novik B et al, Surg Endosc; 2006

Lau H , Annals of Surgery; 2005

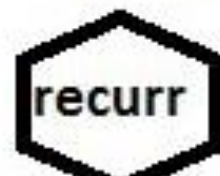Topart P et al, Surg Endosc; 2005

STAPLER



FIBRIN GLUE ?

NO FIXATION



Conclusions/ Suggestions

FS use is feasible.

Less pain, no increase of recurrence rate.

But it may have some **cost drawbacks**,
depending on

country, institution and insurance

No fixation in small (2cm) hernias may be recommended. It does not increase recurrence rate in this group.

Good technique/adequate size mesh

Less pain

most cost-effective

If there is a large hernia over 4 cm, you should use staple fixation
(not enough evidence yet for no fixation)

But you should use only a few
(2-4) staples to avoid postoperative pain.